

Mosquito Coil Smoke Inhalation Effects on Interstitium of Kidney of Albino Rats

NAZIA SIDDIQUE¹, SHAKEELA NAZIR², RUKHSANA JABEEN

ABSTRACT

Aim: To see the mosquito coil smoke inhalation effects on interstitium of kidney of Wistar rats.

Design: Experimental randomized control trial study

Methods: Wistar rats were divided in control (group A) and experimental groups (group B and C) having eight rats in each group. Experimental groups were exposed to mosquito coil smoke for 8 hours/day for two and four weeks respectively. Kidney tissue of albino rats were histologically analyzed.

Results: MCS inhalation in wistar rats causes haemorrhage, congestion of blood vessels, cellular infiltrate and fibrosis in interstitium of kidney.

Conclusion: The results obtained from this study suggest that despite of being the least toxic pesticides, PYR still have harmful effects, as exposure to pyrethroids can cause renal tissue damage .

Key words: MCS Mosquito Coil Smoke, PYR Pyretheroids.

INTRODUCTION

In agriculture and public health pesticides are commonly used to control insects, weeds, animals and vector of disease. Most of pesticides can be harmful to human beings and pests. Mosquitoes have vital importance in hygiene pests and one of the man's worst enemies. In many tropical and subtropical countries especially Asia burning of mosquito coils is one of the most popular ways to reduce mosquito bites. Mosquito coil is mosquito repelling incense, slow burning and cheap device¹. Active mosquito biting is mostly at night so mosquito coil burns for about 8 hours which help in disease control programs. The active ingredients found in mosquito coils are Pyrethrins, Pyrethrum, Allethrin (d-trans-allethrin, Esbiothrin (A form of allethrin), Piperonyl butoxide (PBO), Dibutyl hydroxyl toluene (BHT). During combustion process cadmium, chromium and lead can be released in environment beside organic compound and particulate matter². When mosquito coil is burnt, it evaporates DTA, aldehyde, pyrethrin etc with smoke. It is stated that when one mosquito coil burn it would release same amount of smoke as burning 75 - 137 cigarettes³. Pyrethrin is a natural pyrethrum now commonly known as pyretheroid which is one of the synthetic derivative of pyrethrin^{4,5}. The natural pyrethrum is extracted from the thallus of flower plants genus chrysanthemum cinnerariae folium. Allethrin was the

first synthetic pyrethroid and is a mixture of several forms which was introduced in 1949.

The route of entry of Pyrethrin and pyrethroids is by the ingestion, inhalation or skin contact. These pesticides rapidly metabolized in mammals with little accumulation. In case of acute poisoning it induces adverse health effects which may also be due to chronic exposure⁶. The primary target of pyrethroid toxicity is the nervous system⁷. Chronic exposure of pyrethroids produce various toxic effects like irritation of nose, throat, asthma, skin allergy, and damage to heart, lungs, liver and kidneys^{8,9,5}. Pyrethroids (DTA) induced toxicity at various levels. Lots of work is available on neurotoxic effects of mosquito coil smoke¹⁰. Most of the previous studies have shown morphological, biochemical and cellular changes in the respiratory system¹¹, behavior and neurochemical effects in offspring of rats during prenatal and early postnatal period¹². It is toxic to liver and it also decreased concentration of sperm⁵. This study was designed to see the histological changes in interstitium of kidney with inhalation of mosquito coil smoke.

MATERIALS & METHODS

The study was done in animal house of PGMI Lahore. Albino Wistar rats were used. Rats were provided by Punjab University, Lahore. First step was acclimatization of rats, for which rats were kept in cages for 15 days. Average weight of rats was between 180-200gms. After acclimatization, the animals were randomly divided into three groups A, B and C having 8 rats in each. Group A served as a control, whereas groups B and C were used as

¹Assistant Prof. Anatomy, FMH College of Medicine and Dentistry, Lahore.

²Assistant Proff Anatomy, Rashid Latif Medical College, Lahore.

³Lecturer anatomy, Sargodha Medical College, Sargodha.

Correspondence to Dr. Nazia Siddique, Assistant Professor Email: drnaziasalman@yahoo.com

experimental group. Animals of all three groups were placed in their cages which were labeled by tags.

Group A served as a control so was not exposed to mosquito coil smoke while Group B and C were exposed to mosquito coil smoke for 8 hours/day. Group B were exposed to mosquito coil smoke for two weeks and group C for four weeks. Mosquito coil smoke was given as whole body inhalation. The experiment was conducted in an undisturbed well ventilated room of size 26.2 m³ (3.0 x 3.5 x 2.5). The rats were kept in their respective cages and allowed to inhale the MCS. The mosquito coil was burnt and placed in the centre of room and cages placed equidistant around the mosquito coil so that rats inhaled equal amount of smoke (Garba et al., 2007b).

The observations were recorded in MS Word[®] and Excel^(R) data sheet and summarized in tabulated form. The data was entered and analyzed using SPSS (statistical package for social Sciences) version 17.0. ANOVA test was used to analyze the data for quantitative differences between group A, B and C. The qualitative differences were analyzed by Pearson's chi square test or/and Fisher's exact test, at 5% level of significance. A p-value was considered statistically significant if <0.05.

RESULTS

Renal interstitium is the space present external to basal laminae of the kidney tubules. The renal interstitium consists of collagen fiber, macrophages and fibroblast. In kidney stroma cellular infiltrate, haemorrhage, congestion of vessels and fibrosis were observed in group B and C which was statistically significant when three groups were compared (Table.2, Figs. 1,2,3,4) but absent in group A. For statistical significance experimental groups have been compared between groups and within groups

- p>0.05 Difference insignificant
- *p<0.05 Difference significant
- **p<0.01 Difference considerably significant
- ***p<0.001 Difference highly significant

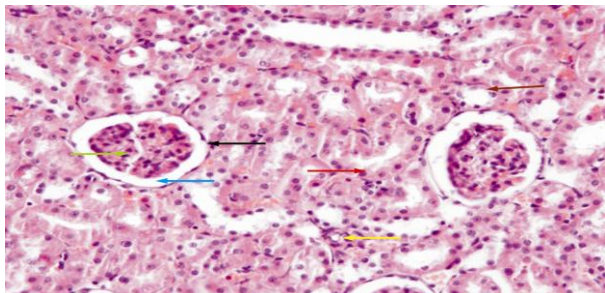


Fig.1. Photomicrograph of the kidney from the control group (A) showing renal corpuscles lined by parietal squamous epithelium (black arrow) with central normal glomerulus (green arrow) surrounded by Bowman's space (blue arrow). PCT lined by

cuboidal epithelium with central nuclei (red arrow) with brush border. DCT lined by cuboidal epithelium (brown arrow). Normal interstitium with blood vessels also seen (yellow arrow). H&E stain X.200

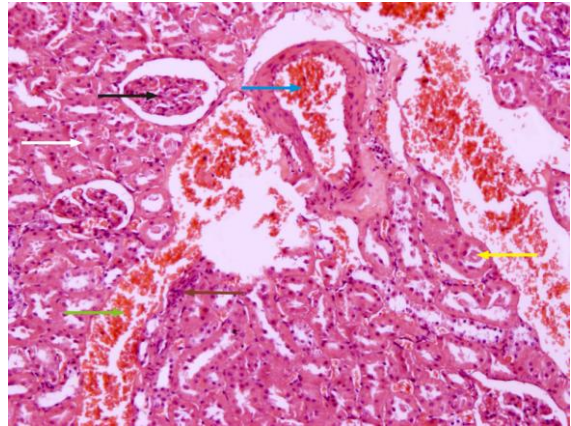


Fig.2: Photomicrograph of cortex of kidney from group (B) showing degenerated glomerulus (black arrow). There is necrosis of tubules (white arrow). Cellular infiltrates are seen (brown). In lumen of DCT protein cast is seen (yellow arrow). Interstitial hemorrhage (green arrow) and congested blood vessel (blue arrow) is seen. H&E stain X.200

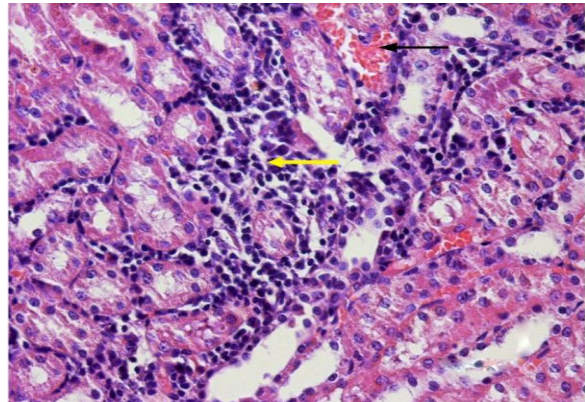


Fig.3: Photomicrograph of the kidney from the group C showing hemorrhage (black arrow) and cellular infiltrate (yellow arrow) in interstitium of kidney. H&E stain X.400

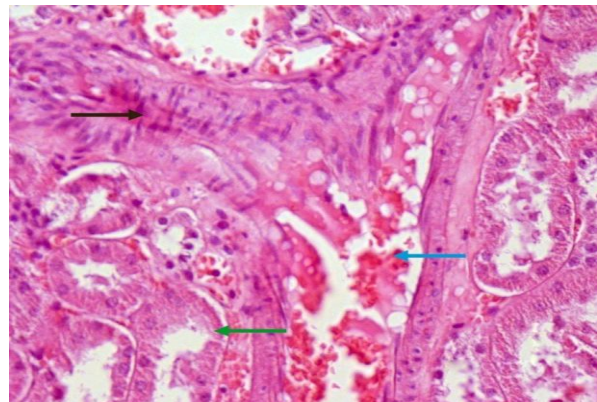


Fig.4: Photomicrograph of kidney from group (C) showing renal fibrosis (black arrow), congested blood vessel (blue arrow) and tubular necrosis (green arrow). H&E stain X.400.

ORIGINAL ARTICLE

Table 1: Detail of animal groups and duration of therapy.

Groups	Duration of therapy	No. of Animals	Remarks
I	0 Weeks	8	Control
II	2 Weeks	8	Exposed to mosquito coil smoke
III	4 Weeks	8	Exposed to mosquito coil smoke

Table 2: Comparison of changes in stromal infiltrate, hemorrhage, congestion of vessels and fibrosis in kidney stroma

Kidney stroma	Status	Group I	Group II	Group III	χ^2 -test (p-value)
Stromal infiltrate	Absent	8(100%)	5(62.5%)	3(37.5%)	0.028*
	Present	0	3(37.5%)	5(62.5%)	
	Total	8(100%)	8(100%)	8(100%)	
Stromal haemorrhage	Absent	6(75%)	1(12.5%)	0	0.002**
	Present	2(25%)	7(87.5%)	8(100%)	
	Total	8(100%)	8(100%)	8(100%)	
Congestion of vessels	Absent	6(75%)	0	0	0.000***
	Present	2(25%)	8(100%)	8(100%)	
	Total	8(100%)	8(100%)	8(100%)	
Stromal fibrosis	Absent	8(100%)	7(87.5%)	1(12.5%)	0.000***
	Present	0	1(12.5%)	7(87.5%)	
	Total	8(100%)	8(100%)	8(100%)	

DISCUSSION

This study was designed to see the mosquito coil smoke inhalation effects on renal interstitium by use of rat animal. The results obtained from the experiment have shown that mosquito coil with DTA as basic ingredient are injurious to rats. According to pervious study⁹ there were signs of toxicity to liver and lung after mosquito coil smoke inhalation but not to the kidney. But most of previous studies were in favour of adverse effects of mosquito coil smoke inhalation both on histopathological and biochemical parameters of kidney as in our study^{13,5,8}.

We observed from our study that in interstitium of kidney the cellular infalammatory infiltrates was seen. These lymphocytic infiltrates indicates the process of phagocytosis of extracellular particles and dead cells. In self defence of the body this increase in lymphocytic infitrate is a good sign¹³. The leakage of contents of the necrotic cell induces injury and inflammation to surrounding tissue. The infiltration and maturation of immune cells are stimulated by decreased oxygen which produce inflammation that may progress to chronic kidney disease¹⁴. According to previous study⁸ structural damage to the kidney also induced functional damage. Because of this functional damage urea and creatinine levels were increased which may affect the erythropoietin production. These changes causing increase in inflammatory cell types.

Fibrosis of renal tissues also seen under light microscope. In previous studies simmlar changes are reported^{15,16}. The fibrogenesis is caused by production of collagen I and smooth muscle actin because of tubular and interstitial hypoxia¹⁴. The hallmark of fibrosis is the increased accumulalation of

extrcellular matrix particularly presence of collagenous fibers. Fibroblast in renal interstitium are considered the principal source of fibrillar matrix. Thus the tubular necrosis and interstitial fibrosis is marked by the deposition of interstitial matrix in association with inflammatory cells, tubular cell loss and fibroblast accumulation^{17,18}. These changes are observed in this study.

In our study stromal hemorrhage and congestion of blood vessels are also observed. The degenerative changes caused by PYR produces the weakness of renal parenchymal tissue. These changes are the major source of congestion^{15,16}.

These findings suggest that coil smoke inhalation is nephrotoxic. But further investigations are required to study the mechanism of toxicity and to see whether these changes are reversible or irreversible in case of exposure to MCS for short duration like 24hrs and one week as changes depends on duration of exposure.

CONCLUSION

The results of present study suggest that despite of being the least toxic pesticides, pyrethroids still have harmful effects, as exposure to pyrethroids can cause renal tissue damage . It is hoped that the present study will produce an awareness and restricted use of pyrethroids insecticides especially at living places.

REFERENCES

1. Krieger RI, Dinoff TM, Zhang X. Octachlorodipropyl Ether (S-2) Mosquito Coils Are Inadequately Studied for Residential Use in Asia and Illegal in the United States. *Environ Health Perspect.* 2003;111:1439-1442.

2. Lin TS, Shen FM. Trace metals in mosquito coil smoke. *Bull. Environ. Contam. Toxicol.* 2005;74:184-189.
3. Liu W, Zhang J, Hashim JH, Jalaludin J, Hashim Z, Goldstein, BD. Mosquito coil emission and health implications. *Environ Health Perspect.* 2003;111(12):1454-60.
4. Walters JK, Boswell LE, Green MK, Heumann MA, Karam LE, Morrissey BF et al. Pyrethrin and pyrethroid illnesses in the Pacific Northwest: A five year review. *Public Health Reports.* 2009;124:149-156.
5. Taiwo VO, Nwagbara ND, Suleiman R, Angbashim JE, Zarma MJ. Clinical signs and organ pathology in rats exposed to graded doses of pyrethroids containing mosquito coil smoke and aerosolized insecticidal sprays. *African journal of biomedical research.* 2008;11:97-104.
6. Macan J, Varnai VM, Turk R. Health effects of pyrethrins and pyretheroids. *Arch Hig Rada Toksikol.* 2006;57(2):237-43.
7. Shafer TJ, Meyer DA, Crofton KM. Developmental neurotoxicity of pyretheroid insecticides: Critical review and future research needs. *Environ Health Perspect.* 2005;113(2):123-136.
8. Garba SH, Adelaiye AB, Mshelia LY. Histological and biochemical changes in the rats kidney following exposure to a pyrethroid based mosquito coil. *Journal of applied science research.* 2007;3(12):1788-93.
9. Okine LKN, Nyarko AK, Armah GH, Awumbila B, Owusu K, Soafia SS et al. Adverse effects of mosquito coil smoke on lung, liver and certain drug metabolizing enzymes in male wistar albino rats. *Ghana medical Journal.* 2004;38(3):89-95.
10. Wolansky MJ, Harrill JA. Neurobehavioral toxicology of pyretheroid insecticides in adult animals: a critical review. *Neurotoxicol Teratol.* 2008;30(2):55-78.
11. Abubakar MG, Hassan LG. Toxicological effects of some mosquito coil brands in experimental rats. *The internet journal of toxicology.* [serial on internet].2007[cited 2010 March 20];4(1). Available from: <http://www.ispub.com/ostia/index.php?xmlFilepath=journals/ijto/vol4nl/mosquito.xml.html>.
12. Sinha C, Agrawal AK, Islam F, Chaturvedi RK, Shukla S, Mathur N et al. Mosquito repellent (pyrethroid-based) induced dysfunction of blood-brain barrier permeability in developing brain. *Int J Dev Neurosci.* 2004;22:31-7.
13. Sakr SA, Mahran HA, Okdah YA. Renal lesion induced by pyrethroid inhalation in albino rats. *OnLine Journal of Biological Sciences.*2004;1(11):1066-1068.
14. Palm F, Nordquist L. Renal tubulointerstitial hypoxia: Cause and consequence of kidney dysfunction. *Clinical and Experimental Pharmacology.* 2011;38(7):474-480.
15. Shona SI, Aasar HSE, Zaki SM, Sayed WM. Morphological and morphometric renal changes in the adult albino rat following oral administration of deltamethrin and the possible protective role of vitamin E. *Journal of Applied Sciences Research.* 2010;6(4): 280-290.
16. Manna S, Bhattacharyya D, Mandal TK, Das S. Repeated dose toxicity of deltamethrin in rats. *Ind. J. Pharmacol.* 2005;37:160-164.
17. Zeisberg M, Neilson EG. Mechanism of tubulointerstitial fibrosis. *J Am Soc.* 2010;21:1819-1834.
18. Hewitson TD. Renal tubulointerstitial fibrosis: common but never simple. *Am J Physiol Renal Physiol.* 2009;296:239-244.